



Letter to the Editor

Unfavorable outcomes in pregnant patients with COVID-19



Dear Editor,

We read with great interest in a recent article by Liu, et al.¹ on the clinical and CT findings of pregnant patients and children with COVID-19. It is clinically oriented, and of great value to the medical workers on the frontline. It revealed that the clinical symptoms of pregnant women were atypical, despite unavailable data about pregnancy outcome in the study. We mainly focused on the pregnancy outcome in patients with COVID-19. It seems that SARS-CoV-2 would be more friendly than its members of the coronavirus family,² such as SARS-CoV-1 and MERS-CoV, which caused severe maternal and neonatal complications.³ Currently, it is too early yet to explicitly determine the effects of SARS-CoV-2 on pregnant women and their fetuses.⁴ Here we explored the impact on pregnancy in patients with COVID-19 from multiple medical centers outside Wuhan, China.

We retrospectively analyzed data from 8 pregnant patients who were laboratory-confirmed from January 24 to February 19, 2020. A detailed analysis of clinical features was shown in Table 1. The age range was 27–33 years. Two (20%) patients had uterine scarring and one patient was twin pregnancy. Five patients (62.5%) developed mild symptoms; three patients (37.5%) showed severe or critical illness requiring ICU admission, one of which undergone ECMO support; four patients (50%) were performed emergency deliveries because of fetal distress or premature rupture of the membrane (PROM). Specially, patient 6 with twin pregnancy had preeclampsia with high blood pressure of 180/100 mmHg and later developed into eclampsia; patient 7 presented with mild symptoms at first and her condition deteriorated rapidly within 6 h after admission, with severe complications including septic shock, septic cardiomyopathy, ARDS, MODS, requiring intubation and mechanical ventilation. Six livebirths and one stillbirth were analyzed. Half of the

livebirths were premature and admitted to NICU; one twin died at the 18 days of birth with severe pneumonia, referred to “white lung”; another twin showed suspected viral pneumonia on chest CT (Fig. 1) and survived after treatment. RT-PCR tests of throat swab specimens for all livebirths were negative.

The cases here highlight three issues that worth stressing. Firstly, unlike previous reports about the favorable outcomes, SARS-CoV-2 might have similar behavior to SARS and MERS, resulting in severe maternal and neonatal outcomes including preterm delivery, PROM, fetal distress, stillborn or neonatal death, admission to ICU or NICU, undergoing endotracheal intubation, septic shock, eclampsia, and MODS. Secondly, those who are older or those who have medical histories such as hypertension and cardiovascular disease tend to fare worse,⁵ other than that, immunocompromised status and physiological adaptive changes during pregnancy might contribute to the rapid deterioration into severe or critical illness. Considering the unfavorable outcomes in pregnant patients, any suspected cases during pregnancy should be systematic screening; closely follow-up for mothers and their fetuses after diagnosis should be emphasized. Finally, despite all livebirths were tested negative for SARS-CoV-2, the stillbirth and one neonatal death at 18-days of birth indicated the potential risk of intrauterine infection.⁶ There should be more evidence to deep investigation in the future study.

The limitation of our analysis is the absence of data on the amniotic fluid, cord blood, vaginal secretion, and breastmilk samples, as all resources were stretched in a pandemic. Moreover, no data about patients at the first or second trimester was reported, since SARS-CoV-2 infection in different trimester might be associated with different outcomes.

In conclusion, SARS-CoV-2 infection during late pregnancy would have severe maternal and neonatal complications, even the neonatal death. Efforts to limit exposure of pregnant women should be strengthened during the outbreak of COVID-19.

Abbreviations: COVID-19, Novel coronavirus disease 2019; SARS-CoV, Severe acute respiratory syndrome coronavirus; MERS-CoV, Middle east respiratory syndrome coronavirus; ARDS, Acute respiratory distress syndrome; MODS, Multiple organ dysfunction syndrome; ICU, Intensive care units; ECMO, Extracorporeal membrane oxygenation; PROM, Premature rupture of membrane; RT-PCR, Reverse transcription polymerase chain reaction.

Table 1
Characteristics, maternal and neonatal outcomes from patients of COVID-19.

Characteristics	Patient 1	Patient 2	Patient 3	Patient 4	Patient 5	Patient 6	Patient 7	Patient 8
Age (years)	29	27	28	33	29	29	32	32
Gravida, Parity	G3P1	G1P0	G2P0	G4P1	G2P1	G2P0	G5P2	G3P1
Gestational weeks	30	34	39+3	38	37+4	31+2	35+2	28+1
Contact history	Yes	Yes	Yes	Yes	Yes	Yes	Yes	Yes
Medical history	None	None	None	Uterine scarring	None	Twin pregnancy	Uterine scarring	None
Complications	Mild anemia	None	None	None	Mild anemia	HF, RF, Mild anemia Eclampsia, PROM	Septic shock, SICM ARDS, MODS	Moderate anemia
Delivery mode	Ongoing pregnancy	Ongoing pregnancy	Cesarian section	Cesarian section	Emergency Caesarean section	Emergency Vaginal delivery	Emergency Caesarean section	Emergency Caesarean section
Signs and symptoms								
Fever (°C) *	36.3	36.6	37.1	37.7	38.6	39.1	39.3	38.9
Cough	+	+	+	+	+	+	+	+
Rhinorrhea	–	–	–	+	–	–	+	–
Sputum production	–	+	+	–	–	–	–	–
Pharyngalgia	+	–	–	–	–	–	+	–
Myalgia or fatigue	–	+	–	–	–	–	+	+
Dyspnea	–	–	–	–	–	+	+	+
SpO ₂	99%	98%	98%	95%	98%	82%	94%	93%
Blood Pressure	103/68	134/100	118/84	110/77	114/76	180/110	100/50	113/74
Pulse	78	75	100	95	101	136	140	102
Respiratory rate	18	19	16	21	19	24	35	25
Fetal distress	No	No	No	No	Yes	Yes, Yes	Yes	Yes
Laboratory Results†								
WBC ($\times 10^9/L$)	7.83	6.98	7.6	6.98	6.48	13.16	6.8	14.48
NEUT ($\times 10^9/L$)	6.25	5.07	5.5	5.07	5.18	11.02	2.28	12.75
LY ($\times 10^9/L$)	1.11	1.53	1.19	1.53	0.01	1.31	0.884	1.09
Eosinophils ($\times 10^9/L$)	0.06	0.02	0.00	0.02	0.01	0.00	0.00	0.03
HGB (g/L)	102	134	133	125	102	108	110	99
D-dimer ($\mu g/mL$)	0.62	1.09	0.40	0.52	1.41	3.76	2.89	0.95
ALT (U/L)	18	26	29	13	11	19.1	137	17
AST (U/L)	10.9	29	22	24	18	47.9	190	29
LDH (U/L)	155	None	None	None	None	450	529	276
CK (U/L)	20	66	55	46	None	258	190	23
Creatinine ($\mu mol/L$)	47	72.3	47	63.2	None	27.9	85	38
BUN (mmol/L)	4.0	3.6	5.4	1.27	None	3.75	2.3	5.1
CRP (mg/L)	1.3	18.4	2.4	55.8	8.43	73.6	>200.0	62.37
Procalcitonin (ng/ml)	0.050	0.270	0.136	0.072	None	3.580	26.800	0.31
Delivery outcomes								
Umbilical cord	None	None	A nuchal cord	Normal	Normal	Normal	Normal	Normal
Placenta	None	None	Normal	Normal	Normal	Normal	Normal	Normal
Amniotic fluid	None	None	Normal	Normal	Normal	Normal	Normal	Normal Opacity, Hypamnion
Maternal outcomes	Survived	Survived	Survived	Survived	Survived	Survived	Survived	Survived
Neonatal outcomes								
Gestational age	None	None	39+3	38+4	37+5	31+2	35+2	28+1
Birthweight (g)	None	None	4200	2367	2585	1520,1720	2700	1530
Apgar score (1,5/min)	None	None	9, 10	10, 10	8, 9	8, 8 and 8, 8	1, 1	8, 9
Severe neonatal asphyxia	None	None	No	No	No	Yes, Yes	Yes	Yes
Neonatal death	None	None	No	No	No	Yes, No	Yes	No
Fetal death or stillbirth	None	None	No	No	No	No, No	Yes	No
Admitted to NICU	None	None	No	No	No	Yes, Yes	No	Yes
RT-PCR test	None	None	Negative	Negative	Negative	Negative, Negative	None	Negative

Abbreviations.

PROM, Premature rupture of membrane. MODS, Multiple organ dysfunction syndrome. ARDS, Acute Respiratory Distress Syndrome. SICM, Septic induced ischemic cardiomyopathy. HF, Heart failure. RF, Respiratory failure. BUN, Blood urea nitrogen.

RT-PCR, Reverse transcription polymerase chain reaction.

* Shown are the highest intrafebrile temperature.

† Reference ranges are as follows: WBC, 3.5×10^9 to $9.5 \times 10^9/L$; NEUT, 1.8×10^9 to $6.3 \times 10^9/L$; LY, 1.1×10^9 to $3.2 \times 10^9/L$; Eosinophils, 0.02×10^9 to $0.032 \times 10^9/L$; HGB, 115 to 150 g/L; D-dimer, 0 to $0.5 \mu g/mL$; ALT, 7 to 40 U/L; AST, 13 to 40 U/L; LDH 120 to 250 U/L; CK, 40 to 200 U/L; Creatinine, 41 to 73 $\mu mol/L$; BUN, 2.6 to 7.5 mmol/L; CRP, 0.068 to 8.2 mg/L; Procalcitonin, 0 to 0.046 ng/ml.

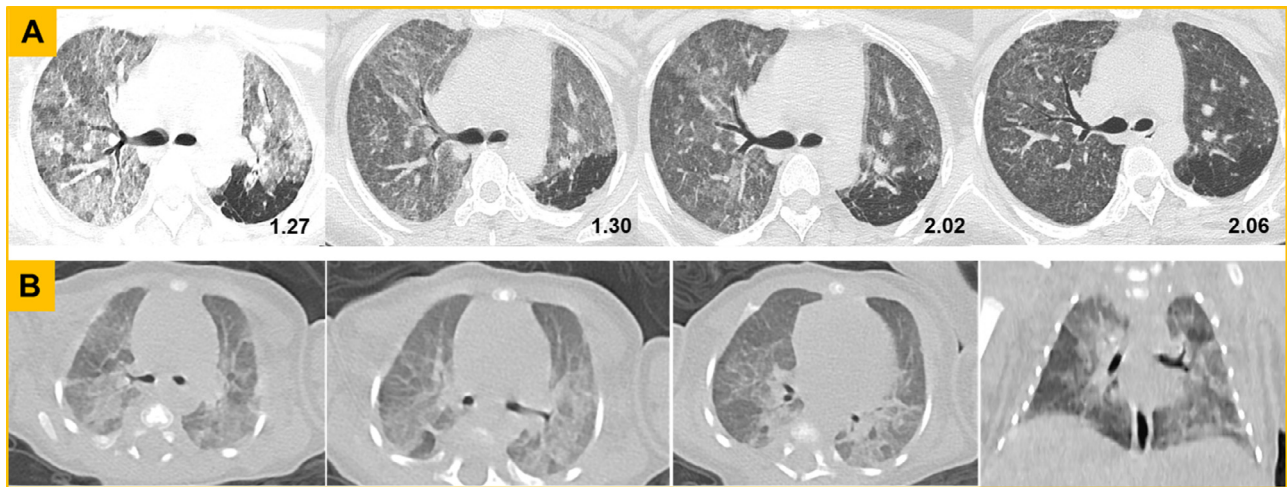


Fig. 1. Chest CT screening from the mother (patient 6) and her twin neonate. (A) CT findings from the mother. The first axial image showed extensive ground-glass opacities (GGO) and nodules. On the following days, the intensity decreased, indicating the lesions were gradually absorbed after effective treatment. (B) CT findings from the twin neonate. The axial and coronal images at the nineteenth day of birth presented with extensive GGO along the bronchovascular bundle or in the peripheral area, and the localized consolidation in dorsal segment of right lower lobe.

References

- Liu H, Liu F, Li J, et al. Clinical and CT imaging features of the COVID-19 pneumonia: Focus on pregnant women and children. *J Infect* 2020;**80**:e7–e13. doi:10.1016/j.jinf.2020.03.007.
- Chen H, Guo J, Wang C, et al. Clinical characteristics and intrauterine vertical transmission potential of COVID-19 infection in nine pregnant women: a retrospective review of medical records. *The Lancet* 2020;**395**:809–15. doi:10.1016/S0140-6736(20)30360-3.
- Assiri A, Abedi GR, Al Masri M, et al. Middle east respiratory syndrome coronavirus infection during pregnancy: a report of 5 cases from Saudi Arabia. *Clin Infect Dis* 2016;**63**:951–3. doi:10.1093/cid/ciw412.
- Luo Y, Yin K. Management of pregnant women infected with COVID-19. *Lancet Infect Dis* 2020;**20**:513–14. doi:10.1016/S1473-3099(20)30191-2.
- Huang C, Wang Y, Li X, et al. Clinical features of patients infected with 2019 novel coronavirus in Wuhan, China. *Lancet* 2020;**395**:497–506. doi:10.1016/S0140-6736(20)30183-5.
- Dong L, Tian J, He S, et al. Possible vertical transmission of SARS-CoV-2 from an infected mother to her newborn. *JAMA* 2020. doi:10.1001/jama.2020.4621.

Wenhui Huang¹

College of Medicine and Biological Information Engineering,
Northeastern University, Liaoning, China
The First Affiliated Hospital, Jinan University, Guangzhou, Guangdong,
China

Zhiwei Zhao¹

Xianning Central Hospital, Xianning, Hubei, China

Zicong He, Shuyi Liu

The First Affiliated Hospital, Jinan University, Guangzhou, Guangdong,
China

Qingxia Wu

College of Medicine and Biological Information Engineering,
Northeastern University, Liaoning, China

Xiaoping Zhang

The Second People's Hospital of Zhongshan, Zhongshan, Guangdong,
China

Xiaoming Qiu

Huangshi Central Hospital, Huangshi, Hubei, China

Huanchu Yuan

Dongguan People's Hospital, Dongguan, Guangdong, China

Ke Yang

The First People's Hospital of Tianmen, Tianmen, Hubei, China

Xiaomei Tang**, Shuixing Zhang*

The First Affiliated Hospital, Jinan University, Guangzhou, Guangdong,
China

*Corresponding author at: Medical Imaging Center, the First
Affiliated Hospital, Jinan University, No. 163, Huangpu West
Road, Tianhe District, Guangzhou, Guangdong 510632, China.

**Corresponding author at: Department of Obstetrics and
Gynecology, the First Affiliated Hospital of Jinan University, No.
163, Huangpu West Road, Tianhe District, Guangzhou,
Guangdong 510632, China.

E-mail addresses: jdtxm04@126.com (X. Tang), shui7515@126.com
(S. Zhang)

¹ Wenhui Huang and Zhiwei Zhao contributed equally to this
manuscript.